

IMPLANT EXPOSURE USING RADIOSURGERY

JEFFREY A. SHERMAN, DDS

High-frequency radiosurgery is one of the most important and versatile instruments in dentistry today, with numerous uses ranging from performing precise surgical incisions to establishing hemostasis. A common and now well-respected word in the field of dentistry, radiosurgery evolved from electrosurgery, and prior to that electrocoagulation. Whilst it is a learned skill that takes time and practice to master, the common use of radiosurgery is due in part to the advancement of the technology as well as the increased research in the field over the years.

Background

The original electrosurgical equipment developed by Coles, Martin, and Ellman has been downsized with the development of more sophisticated waveforms and cutting tips. Dr. Irving Ellman developed the fully filtered waveform combined with a frequency of 3.8 MHz, while Dr. Maurice Oringer wrote the first textbooks on the subject. Dr. John Flocken of UCLA was one of the original educators who brought electrosurgery in the form of participation courses to dental schools and the dental profession.

In 1977, Dr. Arthur Goldstein published a thesis on Radiosurgery in Dentistry. There existed confusion, still prevalent today, regarding the differences between high-frequency and low-frequency devices. Dr. Goldstein realized that there was a need to differentiate the new, higher frequency device that produced lower, cooler temperatures from the low-frequency, higher temperature-producing instruments. The 4-MHz radio wave device differs from the lower frequency, higher temperature electrosurgery machines.

Dr. Goldstein understood the potential for misuse and patient injury by mistakenly using low-frequency electrosurgical devices in the oral cavity. Consequently, he coined the term "radiosurgery" to clearly describe the 3.8- to 4-MHz radio wave device.

Radiosurgery is the removal of soft tissue with the aid of a radio signal which operates within the frequency of 3.0 to 4.0 MHz. The older electrosurgical instruments, while performing similar procedures, operated at a frequency of 1.0 to 2.9 MHz. Research has shown that these low frequencies produced more lateral heat to the surrounding tissues and should be avoided when in close proximity to bone.

Electrosurgery should be considered contraindicated for

periodontal surgery, implant exposure, and delicate surgery, and should be updated to the newer, higher frequency radiosurgery. Radiosurgery at 3.8 to 4 MHz in frequency offers the advantages of a safe, fast, and efficient microincision with an excellent field of visibility.

For proper cutting, as well as coagulation, it is necessary for the instrument to be tuned for the best possible results. Cutting should be smooth and easy with no, or only minimal, sparking being seen. The tissue should be incised with no tissue sticking or clinging to the electrode tip. Sparking on cutting is indicative of too much power, while drag or tissue sticking is indicative of an inadequate power setting. With proper power tuning the electrode will move rapidly through the tissue, making a clean, odorless, microsmooth incision and producing a painless, rapidly healing incision with no or minimal patient discomfort.

Lateral heat is the heat produced to the tissue on either side of the electrode tip. This heat is generated by the resistance of the tissue to the radio wave being transmitted through it. Control of lateral heat to the tissue surrounding the electrode tip is necessary. When making an incision, the radio signal should be applied to any one point for a period of 1 to 2 seconds followed by a waiting or cool-down period of 5 to 10 seconds. The tissue can also be cooled using an air-water syringe or central suction, eliminating the waiting period. Lateral heat can also be reduced by using the fully filtered waveform for making the most delicate incisions in close proximity to the osseous tissue or implant.

Research has shown that this waveform produces the least lateral heat of the four available waveforms. Lateral heat is minimized by proper instrument power tuning, proper waveform selection, and by using a high-frequency radiosurgical instrument operating between 3.8 and 4.0 MHz, versus the old 1.0- to 2.9-MHz low-frequency electrosurgical instruments. The high-frequency radio signal has been shown through research and testing to produce the least possible tissue alteration.

Published research studies confirm adjacent non-target tissue alteration at 15 to 30 μm with the 4-MHz device. The patient experiences a pressureless incision with a minimal amount of bleeding, which often requires no suturing and reduces bacteria, healing time, and discomfort. The radio wave produces a finer, less traumatic incision, and therefore has seen increased usage in all forms of delicate periodontal, oral, implant, and cosmetic surgery.

The Ellman Radiolase II (Ellman International) offers three

*Dr. Jeffery A. Sherman, DDS,
Private Practice, Oakdale, NY, USA*

different waveforms, a frequency of 4 MHz, and autoclavable, radiofrequency- matched micro electrodes and handpieces. A new silver alloy electrode has recently been developed to reduce tissue damage and heat generated to the surgical site. The silver alloy electrode has been shown to produce thermal damage no greater than 10 μm in comparison to tungsten electrodes, which have produced thermal damage as high as 30 μm . Another important advantage of the silver alloy electrodes is their ability to reduce the occurrence of tissue sticking to the electrode tip. This ensures a clean cutting tip, which provides a more precise, microfine incision.

The waveforms include fully rectified filtered for incising tissue and fully rectified for incising tissue with concurrent coagulation being performed. The filtered waveform is used for any incision that may be deep or in close proximity to the bone. This is the waveform of choice for any implant surgery.

The radiosurgical instrument can be finely tuned, and when used with the filtered waveform, can produce microsmooth incisions and perform the most delicate of periodontal procedures. The fully rectified waveform is useful in all forms of tissue removal that are superficial and not close to the bone. A partially rectified waveform is used only for hemostasis of the soft tissue and never to make an incision.

Bipolar surgery has made an appearance in the dental literature. There is some confusion among practitioners as to the difference between monopolar and bipolar surgery. Radiosurgery offers the ability to perform as both a monopolar and bipolar instrument. In the monopolar mode, the incision is made with a microfine, single-frequency- matched surgical wire. This mode is used to remove or recontour soft tissue delicately and precisely. The bipolar mode is used for precise, pinpoint coagulation during microsurgery. Bipolar coagulation uses an electrode with two wider tip wires parallel to each other. The signal travels between the wires, establishing coagulation.

The Radiolase II has both monopolar and bipolar functions. The clinician who is familiar and comfortable with monopolar radiosurgery can continue to use this modality for all general dental procedures. When treatment is in close proximity to implants or large metal restorations, the bipolar modality can be readily utilised. The device is equipped with different handpiece styles and connections to prevent inadvertent use of the wrong modality. It has an adjustable audible tone when activated to prevent any accidental incising of the tissue and complies with all the international safety standards. Disposable, single-use electrodes are included, although the autoclavable

electrodes of earlier models and the new silver alloy electrodes can be used as well.

Clinical Technique

When making incisions for tissue removal and implant exposure, the fine, straightwire Vari-Tip No. 118 electrode (Ellman International) is used in monopolar, or the parallel, straight-wire electrode is used for bipolar surgery. The tip is placed in close proximity to the tissue before the power is activated. The tip is kept parallel to the implant to prevent removal of excessive tissue height. The incision is made in layers, waiting 10 seconds before re-entering the same surgical site. After adequate tissue removal, any necessary hemostasis can be accomplished with the use of the pencil-shaped electrode Nos. 113F and 117. These electrodes are used with the partially rectified waveform. Hemostasis can be performed with the bipolar tips in close proximity to implants to minimize any transfer of heat or radio signal. According to recent CDC dental studies, use of a laser or radiosurgical device can create a smoke plume that develops as a result of thermal destruction of the soft tissue.

Research has shown that the smoke plume may contain toxic gases as well as dead and live cellular tissue. These studies further elaborate that the cellular material may include blood fragments and viruses. All laser use therefore mandates smoke evacuation. These health concerns are being adopted for radiosurgery/electrosurgery to ensure the safety of the patient and healthcare delivery team. Medical and dental experts are recommending the use of a dedicated smoke evacuator that uses a high-efficiency particulate air (HEPA) filter to establish airborne particle reduction. These systems have been designed to use a dedicated vacuum pump, quad filter, and hose with a dedicated inlet nozzle. Nowadays, most dental offices are using a central evacuation system to remove oral debris. These systems were designed for the suction and removal of water, and use a lower volume of air without filtration to accomplish this. Dedicated smoke evacuators work with an increased volume of air needed to remove the smoke plume and send it through a filtration system.

The Surg-e-Vac (Ellman International) was developed primarily for the radio/electro/ laser surgeon. Tests have shown that the Surg-e-Vac has a very high efficiency in airborne particle reduction. This is due to the capture velocity of the unit, which is 150 feet per minute at the inlet wand tip. The filter is designed as a Quad Filtration System (Ellman International), which includes a macro and micro particle

TECHNOLOGY

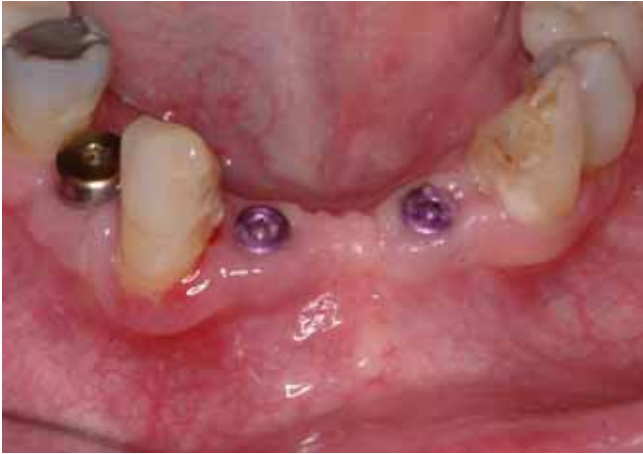

Figure 1 A preoperative view with the three healing caps in position.

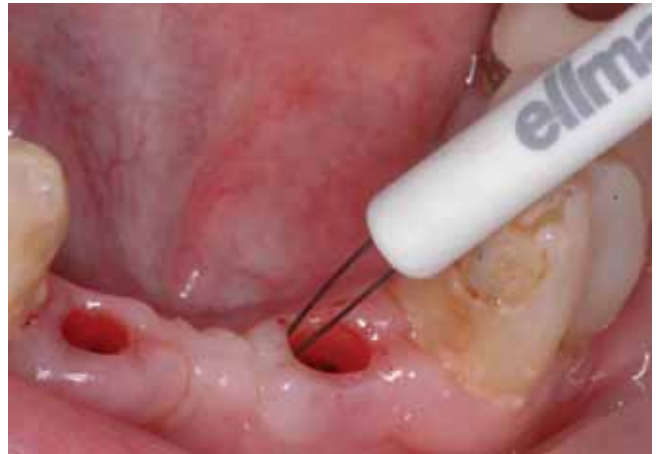

Figure 2 A straight bipolar electrode is used to incise the tissue and expose the implant fully. The Fully Filtered waveform is used to produce the least amount of lateral heat.

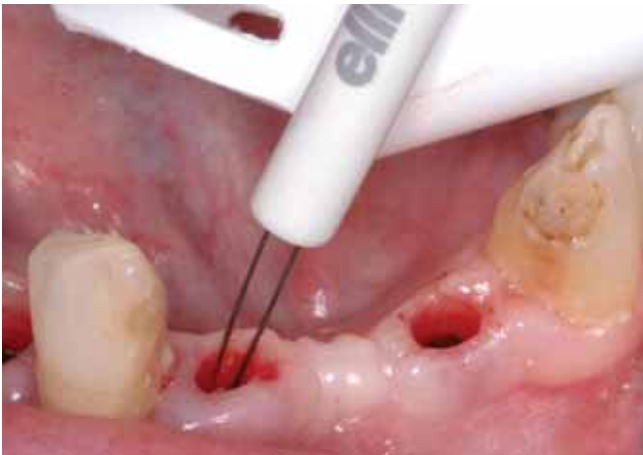

Figure 3 The central suction is placed in close proximity to the surgical site to remove any debris. The bipolar electrode was used to minimize any heat since the radiowave travels only between the two electrode tips.

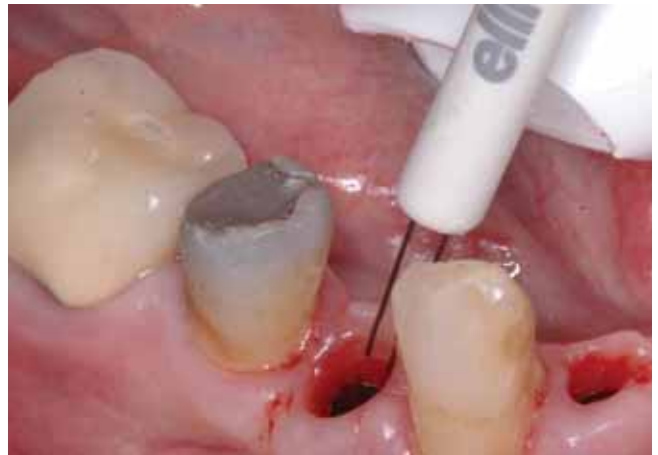

Figure 4 It can be seen that the two tips of the bipolar electrode are parallel to one another. One tip acts as the active electrode and does the cutting while the other acts as the antenna. The radiosignal travels between the two tips.

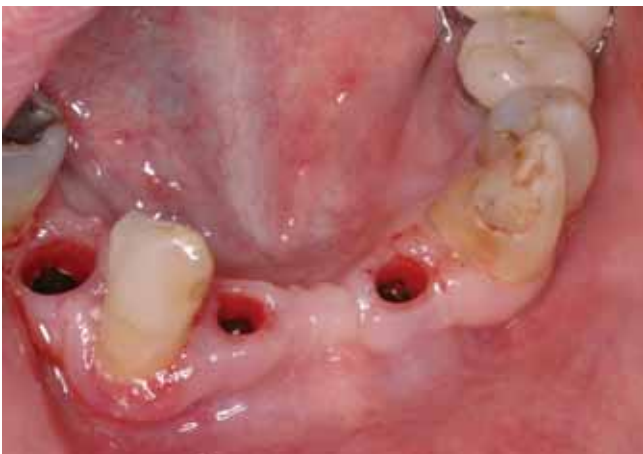

Figure 5 Immediately post-operatively showing the fully exposed implants. The transfer copings can be fully seated without any tissue impingement to insure an accurate impression.

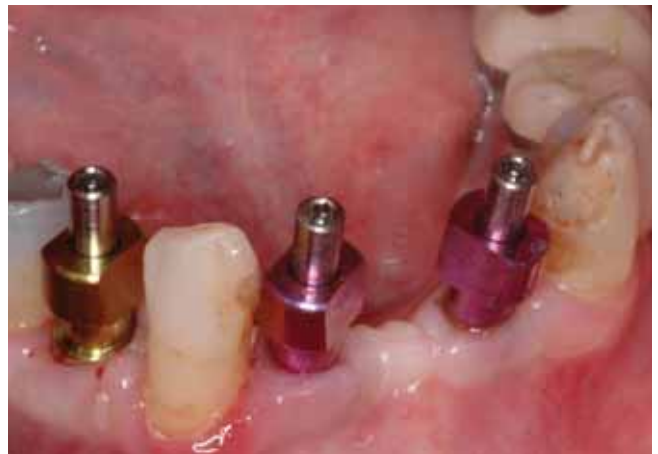

Figure 6 Transfer copings fully seated without any tissue impingement.

trapping section, a HEPA filter for virus removal, as well as a charcoal filter section for odor control. To ensure filtration efficiency, radiofrequency identification technology has been incorporated into the circuitry to monitor the filter function and lifespan.

A postoperative dressing is indicated for all areas of radiosurgery. Areas of minimal tissue removal such as exposing

subgingival decay, troughing crown preparations, or exposing implants can be protected by irrigating the surgical area with Perio-Gard (Colgate-Palmolive), Peridex (Zila), or Listerine (Pfizer).

A coating of Isodent (Ellman International) can also be applied to areas of minor surgery. More extensive tissue removal, as for pre-prosthetic surgery, would warrant a

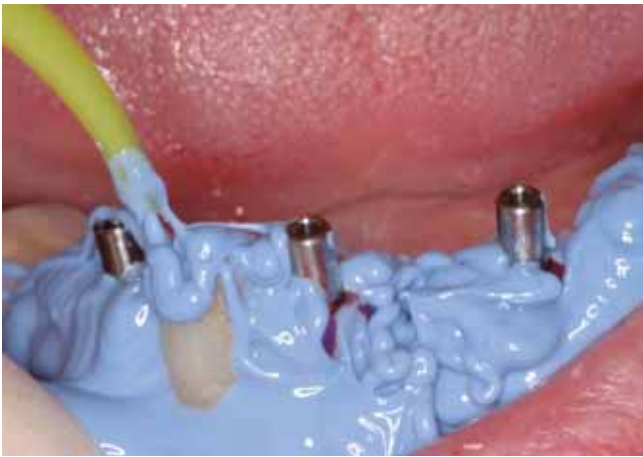

Figure 7 3M Express impression material being injected around the transfer copings.

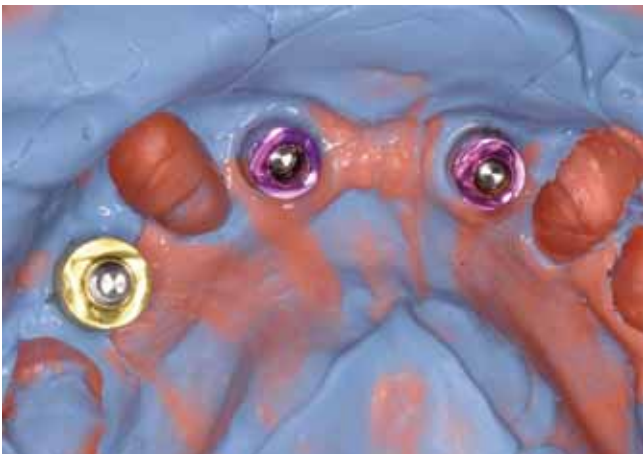


Figure 8 Blood free impression with the transfer copings accurately in position.

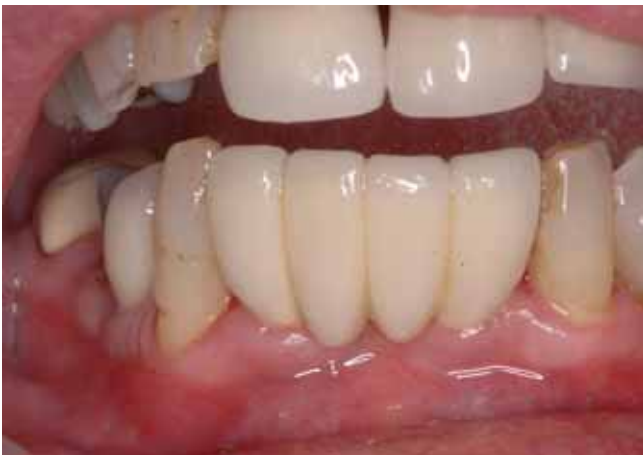

Figure 9 Six month postoperative photo showing healthy tissue healing.

periodontal pack such as COE-PAK (GC America), Zone (Dux Dental), or Barricaid (DENTSPLY Caulk).

Case Presentation

A 52-year-old female was seen in the office for prosthetic restoration of three implants in the mandible. The implants were placed three months prior by a periodontist, and it was established that the healing was sufficient to allow the prosthetic phase to commence. The healing caps were

removed and revealed a slight overgrowth of soft tissue. It was decided to use bipolar radiosurgery to expose the implants fully. The clinical procedure is described in Figures 1 to 9.

Conclusion

High-frequency radiosurgery has numerous clinical applications in the dental practice, from performing precise surgical incisions to establishing hemostasis. This article has described the clinical protocol for using radiosurgery, and includes a case description that uses radiosurgery to expose implants for subsequent prosthetic restoration.

Reprinted with permission from Dentistry Today magazine, copyright Dentistry Today®

Sherman JA. Implant exposure using radiosurgery.
Dentistry Today 2007; 26:4:92-96

References

- Flocken JE. Electrosurgical management of soft tissues and restorative dentistry. *Dent Clin North Am.* 1980;24:247-269.
- Frentzen M, Koort HJ. Lasers in dentistry: new possibilities with advancing laser technology? *Int Dent J.* 1990;40:323-332.
- Kalkwarf KL, Krejci RF, Wentz FM. Healing of electrosurgical incisions in gingiva: early histologic observations in adult men. *J Prosthet Dent.* 1981;46:662-672.
- Kalkwarf KL, Krejci RF, Wentz FM, et al. Epithelial and connective tissue healing following electrosurgical incisions in human gingiva. *J Oral Maxillofac Surg.* 1983;41:80-85.
- Maness WL, Roeber FW, Clark RE, et al. Histologic evaluation of electrosurgery with varying frequency and waveform. *J Prosthet Dent.* 1978;40:304-308.
- Sherman JA. *Oral Electrosurgery: An Illustrated Clinical Guide.* London, England: Martin Dunitz; 1992.
- Sherman JA. *Electrosurgery/Radiosurgery in Fixed Prosthodontics.* St Louis, Mo: Mosby; 1993. In: Hardin JF, ed. *Clark's Clinical Dentistry*; vol 4, chap A.
- Sherman JA. *Oral Radiosurgery: An Illustrated Clinical Guide.* 2nd ed. London, England: Martin Dunitz; 1997.
- Sherman JA. Radiosurgery: the safe, indispensable technology in dentistry. *1000 Gems Update*; Spring 2001;19-21.
- Shuman IE. Bipolar versus monopolar electrosurgery: clinical applications. *Dent Today.* Dec 2001;20:74-81.

Disclosure: Ellman sells the author's textbooks and DVDs.